Marshall B. KETCHUM UNIVERSITY
Southern California College of Optometry

Keratoglobus vs Global Pellucid Marginal Degeneration at Global : An 8-Year Retrospective Case Review

Manveen Bedi, OD, Timothy Edrington, OD, MS, Barry A. Weissman, OD, PhD

PURPOSE

This case study highlights the diagnostic dilemma between keratoglobus (KG) and advanced pellucid marginal degeneration ("global pellucid marginal degeneration", will refer to it as global PMD in the poster). Due to limited literature, the pathophysiological processes of global PMD are not well understood, which makes the diagnosis of global PMD difficult especially when the entire cornea is involved.

CASE HISTORY

- 38 year old Hispanic male presenting for scleral lens evaluation of the left eye (OS)
- **Ocular diagnosis:** Global PMD right eye (OD) involving the entire cornea, PMD OS
- **Ocular history:** Corneal hydrops OS 2002
- **Medical history:** unremarkable
- **Contact lens history:**
  - Hx of intra-limbal design corneal GP lenses
  - Currently: Scleral lens OS only
- Electronic medical records data from initial presentation in 2010 to the present date were analyzed

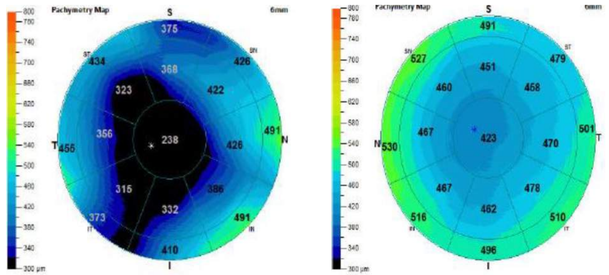

Figure 1: Pachymetry performed on the right eye (on the left side) and left eye (right side) from 2018.

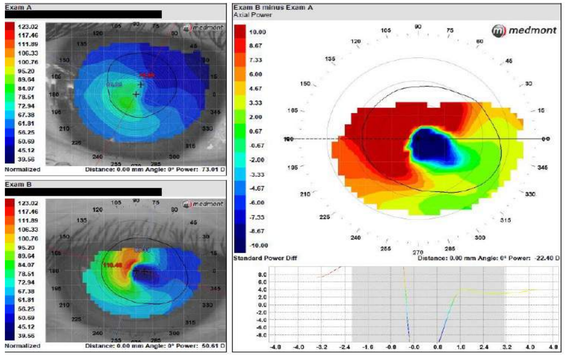

Figure 2: Subtractive axial power map for the right eye from 2010 to 2018

Table 1: Pertinent clinical findings from 2010 vs 2018

	2010	2018
BCVA	20/125 OD 20/20- OS	discontinue lens wear OD 20/20-3 OS
Topography	74.9/66.8 @155 OD 53.1/47.4 @89 OS	110.48/87.38 @74 OD 52.72/48.22 @83 OS
Pachymetry	unavailable	Central: 238 microns OD

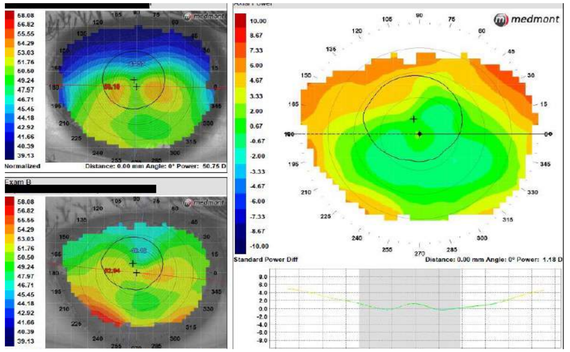

Figure 3: Subtractive axial power map for the left eye from 2010 to 2018

CHALLENGES IN DIAGNOSIS

- Is global PMD a subtype of keratoglobus or is it a distinct entity?
- What are the pathophysiological differences between an advanced ectasia (keratoconus, PMD) vs keratoglobus?

KERATOGLOBUS	PMD
Bilateral condition with limbus-to-limbus corneal thinning	Peripheral inferior thinning 1-2 mm from the limbus
Minimal progression	Typically slowly progressive
Risk of perforation	Minimal risk of perforation

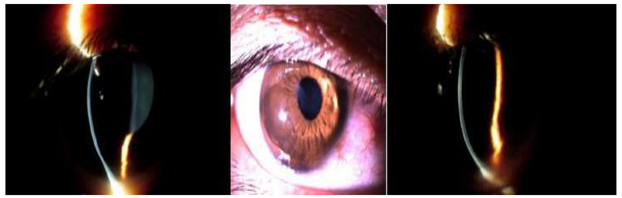

Figure 4: Slit lamp examination with optic section of the right eye (on the left side), gross view of the right eye (in the center), and optic section of the left eye (right side)

CLINICAL CONSIDERATIONS

Significant unilateral inferior thinning suggested global PMD
Progressive ectasia:

1. Consider risk benefit ratio of contact lenses:
   - Visual rehabilitation vs risks of infection, mechanical trauma with the insertion and removal of contact lenses
2. Rare, but risk of spontaneous perforation
3. Corneal transplants with tectonic stability

LITERATURE REVIEW

- Limited literature on the pathophysiological processes between PMD and KG
- Studies have further categorized KG as congenital KG and acquired KG
- Speculations that KC, PMD, and KG as being on a spectrum of the same disease
- **Can global PMD be considered acquired KG?**

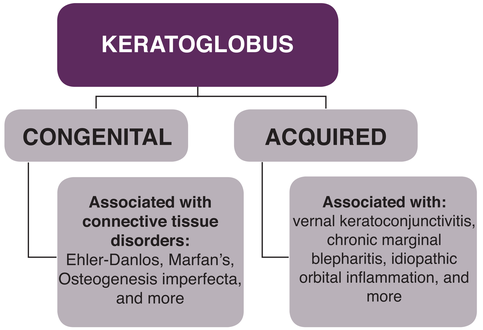

MANAGEMENT

- Discontinue right contact lens wear due to marked progression and severe thinning
  - Consult for transplant
- 3 month routine monitoring
- Pachymetry annually to monitor corneal integrity
- Fox shield and protective eyewear

REFERENCES

1. Jacobs, D.S., Green, W.R., Maumenee, A.E. Acquired Keratoglobus. American Journal of Ophthalmology. 1974: 77 (3): 393-399
2. Karabatsas, C.H., Cook, S.D. Topographic analysis in pellucid marginal corneal degeneration and keratoglobus. Eye, 1996 (10): 451-455
3. Wallang, B.S., Das, S. Keratoglobus. Eye (Lond), 2013: 27 (9): 1004-1012