Vision Rehabilitation Post-INTACs with Hybrid Lenses: A Case Report

Author: Tiffany Andrzejewski, OD, FAAO

Background: Keratoconus is a corneal ectasia characterized by progressive paracentral corneal thinning resulting in irregular astigmatism and vision impairment. INTACs have been used for more than 14 years in keratoconic eyes to reshape the cornea, reduce corneal steepening and refractive error, and avoid or delay the need for a corneal transplant(1,2). INTACs are polymethyl methacrylate semicircular inserts that remodel the corneal contour by acting as spacers between the collagen layers, elevating the midperipheral anterior cornea while flattening the central anterior cornea. However, majority of patients still require vision rehabilitation with contact lenses following INTACs(3). Nevertheless, contact lens fitting challenges have been reported in literature after implantations of intrastromal corneal ring segments(4,5). Although sclerals seem like an obvious option as they're designed to vault all corneal irregularity, they may not be optimal depending on the patient's profession and lifestyle.

These 2 case reports describe patients who were referred for scleral lens fitting and were ultimately refit instead into hybrid contact lenses which improved vision and provided good comfort for all day wear.

Case 1 Description: A 23 year old Hispanic male with keratoconus presented as a referral for scleral lens fitting. He had undergone "epi-on" crosslinking in 2013 then implantation of INTACs OU in 2017. He had previously failed in corneal gas permeable lenses due to poor comfort as well as soft toric lenses due to vision. He presented wearing Biofinity toric soft contact lenses that he was disposing of every 1-2 months and wearing as extended wear. Entering acuities were 20/40-2 OD with Biofinity toric -1.00-1.25x060 and 20/25-2 OS with Biofinity toric PL-0.75x130. His main complaint was poor distance vision and ghosting, especially at night. Corneal topography of both eyes showed a central cone with ring of peripheral flattening due to the INTAC segments. K readings were 7.04/6.61 OD and 8.01/6.67 OS. Slit lamp examination showed Fleischer rings OU but no scarring and migration of the INTAC segments so they were touching nasally but without overlap OD and there was 2.4mm of overlap nasally from 7:30 to 8:30 OS. He works as a public safety officer with 12-14 hour shifts and is an MMA fighter in his spare time. Hybrid lenses were recommended instead of sclerals as he needed to wear lenses to work day and night and also intended to fight in them and there was a concern of trauma due to impact with scleral lenses. He was fit successfully with SynergEyes UltraHealth lenses.

Case 2 Description: A 68 year old Caucasian male with keratoconus presented as a referral for a specialty lens fitting. He had undergone INTACs surgery OD only in 2008. He presented wearing small diameter, fenestrated corneal gas permeable lenses with a BCVA of 20/30-2 OD, 20/25-3 OS. He specifically had issues with corneal GPs fogging up, nighttime glare/halos, and variable vision. He was struggling to comfortably wear his GPs more than 12 hours/day when his schedule required him to wear them for 18hrs, in addition he did not feel safe to race at 100mph speeds with his habitual lenses. He is a real estate investor who travels and works extremely long hours and is an Indy car driver in his free time. Corneal topography showed a small central cone with ring of peripheral flattening due to 2 INTAC segments OD, OS had a small central cone. K reading were 6.83/7.18 OD and 7.21/7.09 OS. Slit lamp examination showed 2 horizontally placed INTAC segments OD only. Both corneas had a small and slightly elevated apical scar but only OD displayed mild apical staining. Both eyes had trace nuclear sclerotic cataracts. Scleral lenses were tried in office but the patient was turned off by their increased size. He had worn SoftPerm hybrid lenses before they were discontinued so he was open to trying hybrids instead. He was successfully fit with SynergEyes UltraHealth lenses and obtained improved acuities of 20/25-2 OD, 20/25+2 OS with improved comfort and vision stability.

Lens Fitting Case 1: Diagnostic fitting was performed following the SynergEyes UltraHealth fitting guide and the first pair of lenses were ordered. Wearing SynergEyes UltraHealth parameters OD: 150/flat/-2.25 and OS: 100/flat/PLANO his vision improved to 20/20-3 at distance OU and J1 at near OU. Both lenses decentered slightly inferior but had central clearance, ILZ thinning, OLZ bearing and adequate movement. At his 3 week follow up he was still seeing 20/20-3 and reported a significant improvement to nighttime vision and ghosting/glare resolved. At his final follow up 1 month later he was wearing the lenses successfully for 15-17hrs and able to participate in nighttime patrols without any visual problems.

Case 1 Topographies of Right and Left Eye Demonstrating Presence of Keratoconus

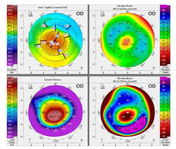

Figure 1A Case 1 topo OD[4]

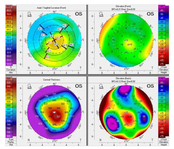

Figure 1B Case 1 topo OS[2]

Migration of INTAC Segments OD and Overlap of INTAC Segments Nasally OS

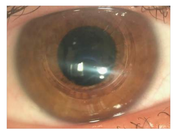

Figure 2A Case 1 OD

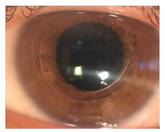

Figure 2B Case 1 OS

AS-OCT Over Hybrid OD, OS

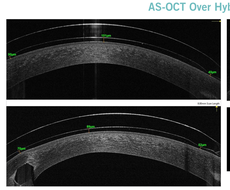

Figure 3A Case 1 AS-OCT OD

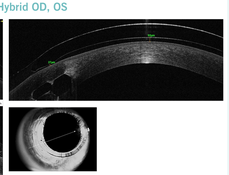

Figure 3B Case 1 AS-OCT OS

Case 2 Topographies of Right and Left Eye Demonstrating Presence of Keratoconus

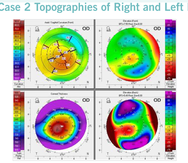

Figure 4A Case 2 topo OD

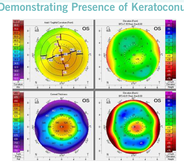

Figure 4B Case 2 topo OS

AS-OCT Over Final Hybrids OD, OS

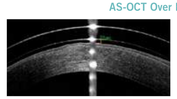

Figure 5A Case 2 AS-OCT OD

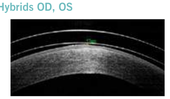

Figure 5B Case 2 AS-OCT OS

Lens Fitting Case 2: Diagnostic fitting was performed following the SynergEyes UltraHealth fitting guide and initial parameters were ordered: OD 250/flat/-8.50, OS: 250/flat/-7.75. Upon dispense, both lenses exhibited good centration with central clearance but ILZ bearing was observed so the lenses were re-ordered with a medium skirt including an over-refraction of -0.50sph OD, +0.50sph OS. The 2nd pair of lenses ordered were: OD 250/med/-9.00, OS: 250/med/-7.25. The patient picked them up without an appointment, began wearing them and returned 2 weeks later for follow up. Upon follow up, vision was 20/30-2 OD, 20/25-2 OS, he remarked that night vision was incredible, vision was stable no matter what activities he was doing, and although comfort was good, he noted a little bit of pain upon OD CL removal after 12+hrs of wear. Upon slit lamp examination, the right cornea exhibited staining in the area of the ILZ just outside the inferior INTAC segment from 6:00-9:00 which corresponded with ILZ bearing. The left cornea was clear and the lens provided apical clearance, ILZ alignment and adequate movement. Finding that the ILZ was problematic over the INTAC segments OD both with the medium skirt and a diagnostic trial of the steep skirt, he was refit with the UltraHealth FC design. The FC design incorporates aspheric reverse geometry into the GP portion and has a flatter base curve allowing for a better fit on oblate corneas. The new parameters ordered for OD were: UH FC 505/med/-3.75. At the dispense visit, OD vision improved to 20/25-2 and there was central clearance now with desired ILZ thinning. The INTAC segments of the right eye caused the cornea profile to be more oblate than originally perceived causing the need for the design change. Upon the final follow up visit 3 weeks later, he presented with significant improvement in end of day comfort and pain upon lens removal had resolved. OS continued to remain a good fit with the UltraHealth lens. Final BCVA was 20/25-2 OD, 20/25+2 OS and neither cornea displayed any staining upon removal of the lenses after 6.5 hours of wear.

Case 2: Clearance Over INTACs Seen with Finalized UltraHealth FC Design OD

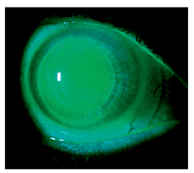

Figure 6 Case 2 Final UltraHealth FC Hybrid OD Over INTACs

Lens Fitting/Follow Up: Case 2 Lens Parameters Ordered

1. OD 250/14.5/flat/-8.50 (OR +0.50)
   OS 250/14.5/flat/-6.50 (OR -0.50)
2. OD 250/14.5/med/-7.25 (OR Plano)
   OS 250/14.5/med/-9.00 (OR Plano)
3. OS 505/14.5/med/-3.75 (FC design)

Conclusion: Many different contact lenses can be used after implantation of INTACs (5-9). Clinical wisdom within the literature reports that contact lens fitting following INTACs can be challenging due to shape changes arising from the ring segments. There will be an increase in corneal elevation directly above the ring segments and a depression just adjacent to it (5,6). As the ring segment is elevated, standard design GP lenses aligning with the central apex may lead to excess bearing on the segments, causing decentration, corneal insult and discomfort. If the contact lens aligns the ring segments, this can result in excess sagittal depth centrally leading to central bubble formation and/or insufficient edge clearance, which may result in binding. This is often why scleral lenses may be preferred as they completely vault all corneal irregularity resting on the sclera eliminating the afore mentioned issues and any concerns of corneal insult and discomfort are avoided (8).

However, in very active patients whose lifestyle and activities require extremely long wear due to the demands of their profession, the UltraHealth hybrid lens can be a great option because it not only allows high oxygen transmission to promote tear circulation, the GP material also provides enhanced vision for those patients with irregular corneas. UltraHealth and UltraHealth FC embody ideal contact lens qualities: the soft skirt improves lens centration, as well as comfort; oxygen transmissibility is optimum with the GP center at a Dk of 130, and the SiHy skirt at a Dk of 84. Furthermore, there is UVA and UVB protection. UltraHealth provides a physiologic advantage over scleral lenses in that it allows for a tear exchange rate two times quicker than scleral contact lenses (2.03%/min in hybrids vs 0.02-0.28%/min in sclerals) to maintain corneal health which is an important consideration for longer wear time (10,11).

References

1. Powers DP, Alio JL. Intracorneal ring segments in ectatic corneal disease – a review. Clin Experiment Ophthalmol. 2010;38(2):154-167.
2. Rabinowitz YS. INTACS for Keratoconus. Int Ophthalmol Clin. 2010;50(3):63-76.
3. Alfonso JF, Lisa C, Fernandez-Vega L, et al. Intrastromal corneal ring segment implantation in 219 keratoconic eyes at different stages. Graefes Arch Clin Exp Ophthalmol 2011; 249:1705–1712
4. Dalton K, Sorbara L. Fitting an MSD (mini scleral design) rigid contact lens in advanced keratoconus with INTACS. Cont Lens Anterior Eye. 2011 Dec; 34(6):274–81.
5. Wachler L, Harris M. Contact lens fitting over intrastromal corneal rings in a keratoconic patient. Optometry. 2004 Jan;76(1):48-54.
6. Nepomuceno R, Boxer Wachler BS, Weissman BA. Feasibility of contact lens fitting on keratoconus patients with INTACS inserts. Cont Lens Anterior Eye 2003;26:175–180.
7. Smith KA, Carrell JD. High-Dk piggyback contact lenses over Intacs for keratoconus: A case report. Eye Contact Lens. 2008;34:238–241.
8. Alipour F et al. Mini-scleral Contact Lens for Management of Poor Visual Outcomes after Intrastromal Corneal Ring Segments Implantation in Keratoconus. J Ophthalmic Vis Res. 2016 Jul-Sep; 11(3): 252–257.
9. Smith KA, Carrell JD. High-Dk piggyback contact lenses over Intacs for keratoconus: a case report. Eye Contact Lens. 2008 Jul;34(4):238-41.
10. Achenbach P, Bergmanson J, Möller M, Walker M, Powell D, Hemmati K, Skidmore K. Tear exchange beneath a vaulted hybrid contact lens. Contact Lens and Anterior Eye. 2018 Jun; 41(1): S39–40.
11. Skidmore, Kelsea V. et al. A measure of tear inflow in habitual scleral lens wearers with and without midday fogging. Contact Lens and Anterior Eye. Nov 2018.