

# Piggybacking Prosthetic Iris Lenses and Sclerals: Cosmetic and Visual Correction

Andrew Fischer, OD; Sarah Henderson, OD; David Kading, OD, FAAO, FCLSA  
Specialty Dry Eye and Contact Lens Research Center, Seattle, WA

## Introduction

A congenital iris coloboma is a rare condition which can cause significant visual aberrations. This case outlines managing visual aberrations and cosmesis in a patient with bilateral iris colobomas.

## Case Presentation

A 24-year-old Indian female presented for a second opinion, having been told she may have keratoconus. She complained of distorted lights, glare, and ghosting especially at night.

Her ocular history was positive for iris and retinal coloboma OU, ICL surgery OD, congenital cataract OD, and LASIK surgery OS. The congenital cataract and retinal coloboma OD were so extensive that visual improvement potential was minimal.

Entering VAs were 20/400 OD and 20/30 OS. Corneal topography was performed to address possible keratoconus; the patient did not present with keratoconus, but irregular astigmatism OD and temporally decentered LASIK treatment OS contributing to her visual complaints.

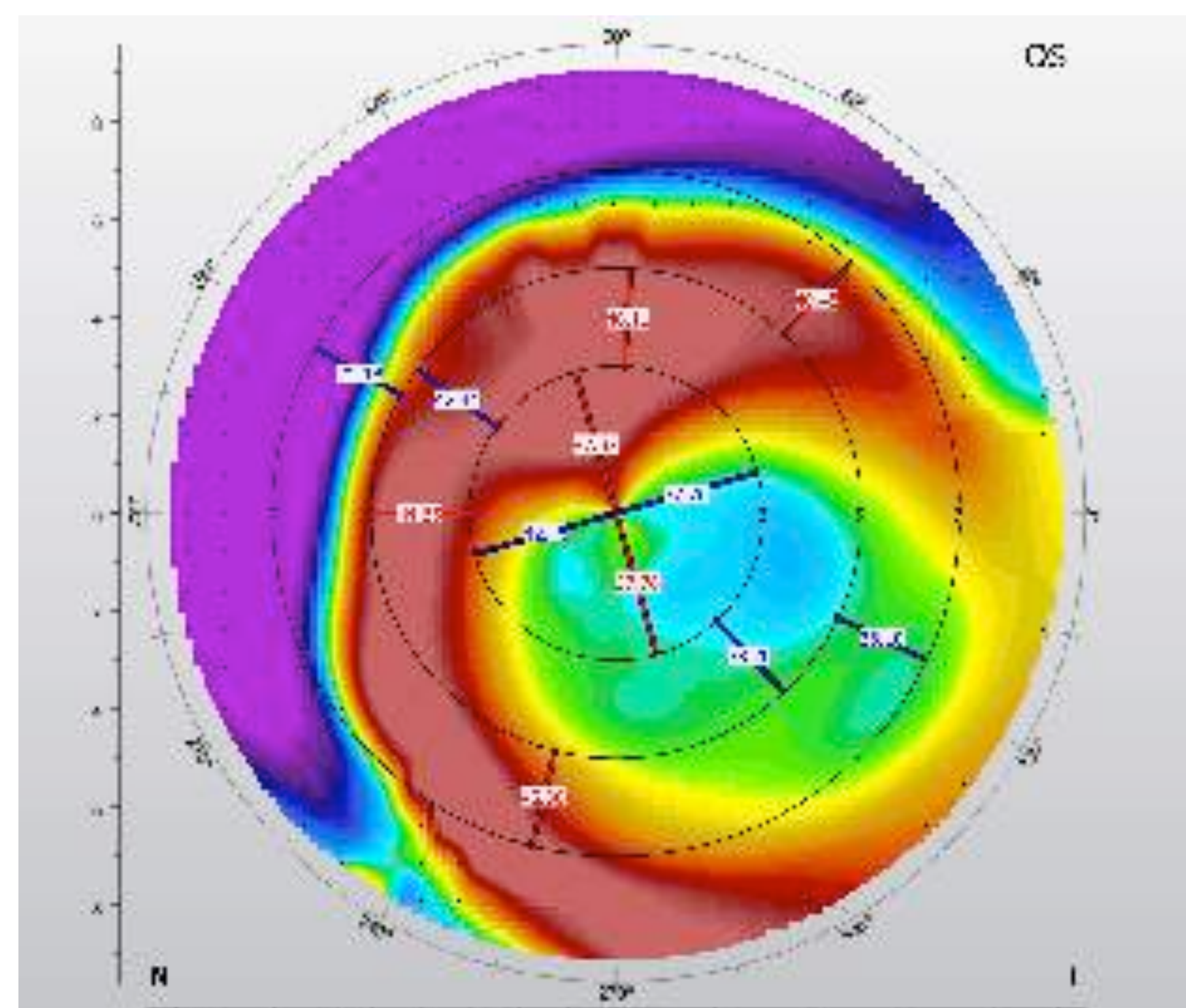


Image 3 shows the OS topography at the initial exam; note the inferior and temporal decentration of LASIK treatment.

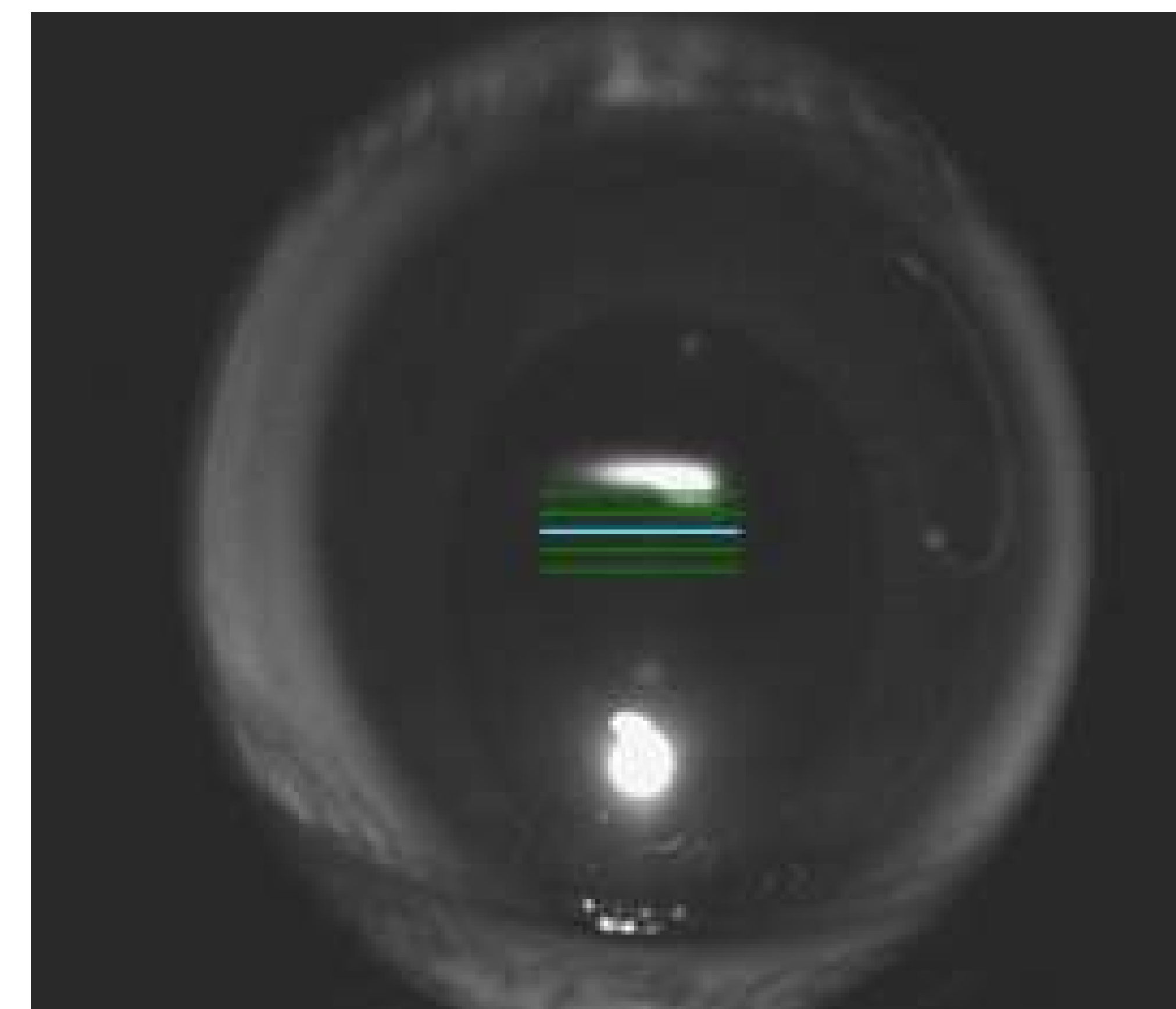


Image 1 shows the OS during an anterior segment OCT scan. Note the iris coloboma, causing vertical elongation of the pupil.

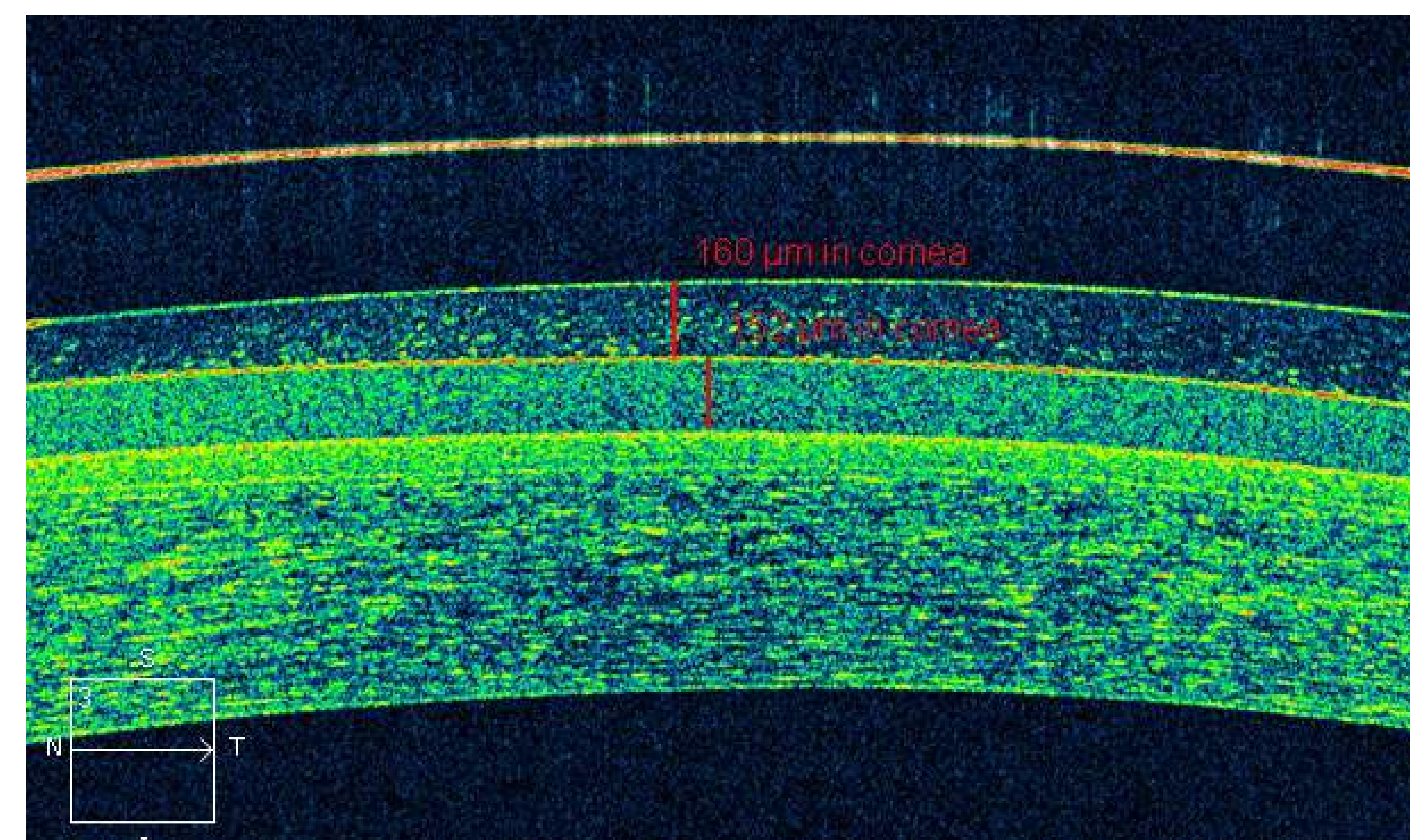


Image 2 shows clearance of 160 microns over the prosthetic iris contact lens.

## Methods & Materials

The patient was fit into a Valley Custom Stable Elite OS improving vision to 20/25; the patient reported blur was improved with the scleral lenses, but still bothersome at times. The lens was fit with a central clearance of 170 microns and the optic zone was enlarged to aid in acuities and reduce distortion.

She also questioned what could be done to improve the appearance of the iris. The patient was fit into Alden HP 49 soft CL. The OS lens was to be worn beneath the scleral. She noted decreased distortion with the piggyback system; VAs were 20/400 OD, 20/20-2 OS, and the patient was happy with the cosmetic improvement.



## Discussion

In this case, both a scleral lens and a prosthetic iris lens were fit in a piggyback system in order to minimize glare and distortion, while also addressing the patients concerns about the cosmetic appearance of her eyes.

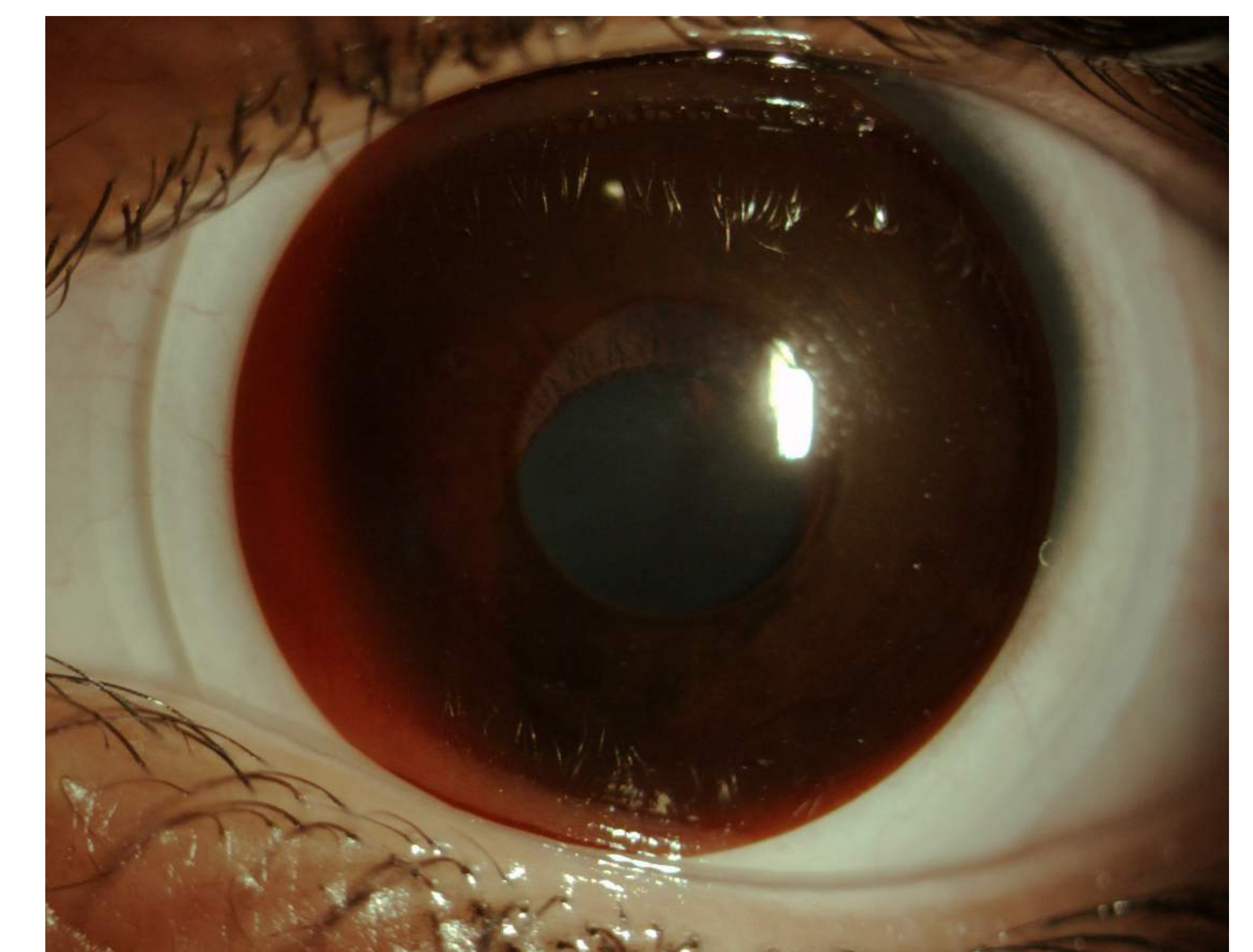


Image 4 shows the OS with both the prosthetic iris lens and scleral lens on the eye.

## Acknowledgements

This study was supported by Specialty Dry Eye and Contact Lens Research Center.

## Contact Information

For more information, please contact Dr. Andrew Fischer at [DrFischer@specialtyeye.com](mailto:DrFischer@specialtyeye.com).