Marshall B. KETCHUM UNIVERSITY
Southern California College of Optometry

The Contact Lens' Role in the Management of Pediatric Blepharokeratoconjunctivitis

Andrew M. Vo, OD Timothy Edrington, OD, MS, FAAO

INTRODUCTION

Blepharokeratoconjunctivitis (BKC) is a condition characterized by inflammation of the eyelids and dysfunction of the meibomian glands, which can lead to secondary inflammation of the conjunctiva and cornea. Signs can range from frequent chalazia, to corneal neovascularization, to corneal thinning and perforation. Without appropriate treatment, severe cases can result in visually significant corneal scarring and subsequent loss of vision. [1]

An 8 year old hispanic female with a history of severe blepharokeratoconjunctivitis presented as a referral for a specialty contact lens evaluation OD, having never worn glasses nor contact lenses in the past. Despite chronic management, her condition led to severe stromal scarring which induced a visually significant amount of irregular astigmatism.

CASE HISTORY

Chief Complaint:	Longstanding blurry vision OD. Recurrent red eye OD approximately every 6 months since 2 years of age.
Ocular Hx:	Severe blepharitis OU.
Medical Hx:	None
Ocular Medications:	Artificial tears PRN, OcuSoft lid scrubs QHS
Systemic Medications:	None
Unaided Visual Acuity:	OD: 20/400 (PH: 20/50) OS: 20/20
Manifest:	OD: +2.00-3.00x180 20/125 OS: +0.50-0.50x180 20/20
Distance Cover Test:	Intermittent 8pd right exotropia
Anterior Segment:	OD: dense stromal scarring over visual axis with overlying neovascularization. Scalloped lid margins, chalazion UL. Grade 2+ superificial punctate keratitis. OS: peripheral stromal scarring with overlying neovascularization. Scalloped lid margins. Grade 2+ superficial punctate keratitis.
Posterior Segment:	Pink and healthy optic nerve OU, Flat and even macula OU.
Differential Diagnoses:	Vernal keratoconjunctivitis, phylectenular keratoconjunctivitis, atopic keratoconjunctivitis

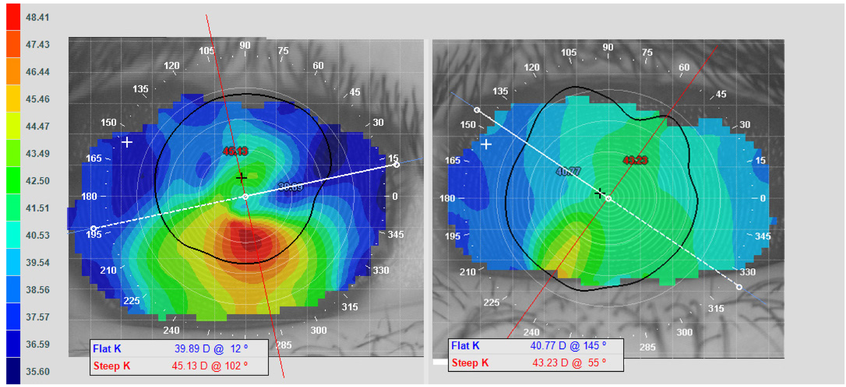

Figure 1: Axial map corneal topography OD and OS.

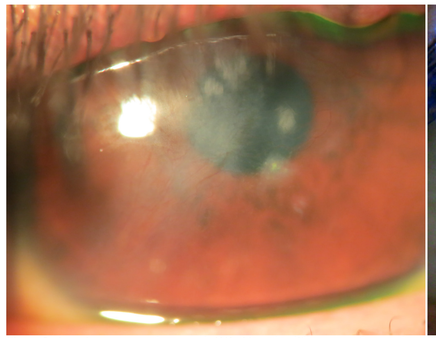

Figure 2: Anterior segment photograph OD. Note the diffuse area of stromal scarring and overlying neovscularization.

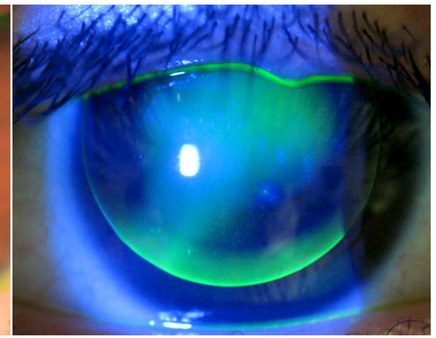

Figure 3: Flourescein pattern of GP contact lens OD.

Material	BC (D)	Power (D)	Dia (mm)	OZD (mm)	Secondary Curve (mm)	Peripheral Curve (mm)	CT (mm)
Optimum Comfort (Dk = 60)	52.50	-8.00	9.6	7.2	9.00 x 0.5	12.00 x 0.2	0.12

Table 1: GP contact lens parameters OD.

DISCUSSION

BKC is a common condition leading to pediatric eye clinic referral (estimated to be 12-15% of cases). Initial symptoms include eye rubbing, chronic bilateral hyperemia, photophobia, and epiphora. Recurrent chalazia are frequently encountered, along with discharge and crusting of the lids in the morning. The condition can sometimes be unnoticed until photophobia or reduced vision occurs.

Common long-term treatments are antibiotics, tear supplements, omega-3 supplements and eyelid hygiene; however, most of these options are based on adult studies on meibomian gland dysfunction and acne rosacea induced keratitis.[1] Corneal involvement, although only present in 5% of cases, generally indicates acute management with corticosteroid and antibiotic drops, the strength of which are determined by disease severity and the presence of stromal involvement.[2]

In our patient, the presence of corneal neovascularization that extended over the visual axis was concerning. To avoid hypoxic-induced progression, the patient was fit into a high-DK corneal RGP (see Table 1) instead of a scleral RGP. A large diameter contact lens (relative to the corneal diameter) was chosen due to the irregularity and scarring extended out towards the limbus.

Since no refractive correction was prescribed in the past, mild refractive amblyopia is likely the cause of her decreased visual acuity. However, the degree of scarring may have also limited the patient's visual potential. Full-time wear with patching 2 hours a day was recommended. The patient currently has follow-up appointments every 3 months to monitor visual progression in her right eye.

CONCLUSION

BKC can be difficult to diagnose in children due to the inability to conduct a thorough slit-lamp examination. Frequent chalazia or recurrent conjunctivitis are hallmark initial signs, and should be used as differentiation from other conditions such as herpes keratitis, or allergic or viral conjunctivitis.[3]

Early diagnosis and management is important to decrease the risk of vision loss from corneal involvement and secondary amblyopia. GP contact lenses can be utilized to correct an irregular cornea in children as a result of BKC. They also serve as an accurate refractive correction to initiate the treatment and management of amblyopia.

REFERENCES

1. Viswalingam, M., Rauz, S., Morlet, N., & Dart, J. K. G. (2005). Blepharokeratoconjunctivitis in children: diagnosis and treatment. The British Journal of Ophthalmology, 89(4), 400–403. http://doi.org/10.1136/bjo.2004.052134
2. Moritz Claudius Daniel, Michael O'Gallagher, Melanie Hingorani, Annegret Dahlmann-Noor & Stephen Tuft (2016) Challenges in the management of pediatric blepharokeratoconjunctivis / ocular rosacea, Expert Review of Ophthalmology, 11:4, 299-309, DOI: 10.1080/17469899.2016.1209408
3. Hammersmith, K. (2006). Blepharokeratoconjunctivitis in Children. Yearbook of Ophthalmology,2006, 106-107. doi:10.1016/s0084-392x(08)70291-0