



How a Well-Fitted Scleral Contact Lens With a High Dk Material Can Facilitate Regression of Neovascularization



Hong T. Nguyen OD, Thomas P. Arnold OD FSLs

INTRODUCTION

Radial keratotomy (RK) is a refractive surgical procedure developed in 1974 to reduce reliance on corrective lenses. A diamond blade is used to create corneal incisions to flatten the cornea in order to correct myopia and astigmatism. Due to the nature of the technique, myriad complications arose in the years to follow including corneal scarring, unstable vision, severe dry eye, neovascularization and an increased risk of infection. Although RK is not practiced much anymore, it is something that we currently manage.

Scleral lenses are a large diameter rigid gas permeable lens that completely vaults over the cornea and lands on the sclera. They are designed to accommodate various corneal conditions including dry eye, corneal irregularities, and corneal ectasias.

CASE SUMMARY

Fifty-six year old Caucasian male presented with complaints of blurry vision and contact lens discomfort in both eyes. He had a history of radial keratotomy performed on both eyes in 1983 and had been wearing hybrid contact lenses for the past 12 years. Upon slit lamp examination, it was noted that he had 4+ injection 360 degrees and severe corneal neovascularization. These follow surgical incisions in both eyes. The decision was made to refit the patient with Synergeyes VS, which comes in a very high Dk material - Menicon Z. It may be fit with minimal corneal vaulting to allow for high oxygen permeability.

INITIAL EXAMINATION

Manifest Refraction

OD: +2.50 - 2.50 X 065 20/200
OS: +2.25 - 1.25 X 140 20/50

HVID

OD: 11.9mm
OS: 11.9mm

Dominant Eye

Right Eye

Keratometry

OD: 36.00 @ 060/42.00 @ 150
OS: 28.75 @ 133/35.00 @ 043

Slit Lamp Examination

OU: Trace blepharitis, 4+ conjunctival injection, RK scars with 5mm neovascularization, trace nuclear sclerosis

FINAL SCLERAL LENS

SynergEyes VS	Lens Design	SynergEyes VS
8.4	BC	8.2
3500 um	SAG	3400 um
16.0 mm	DIA	16.0 mm
-4.00 D	POWER	-5.25 - 0.75 X 090
0.24 um	CT	0.23 um

VA with Scleral Lenses (Mono Vision)

DVA OU: 20/20
NVA OU: 20/20

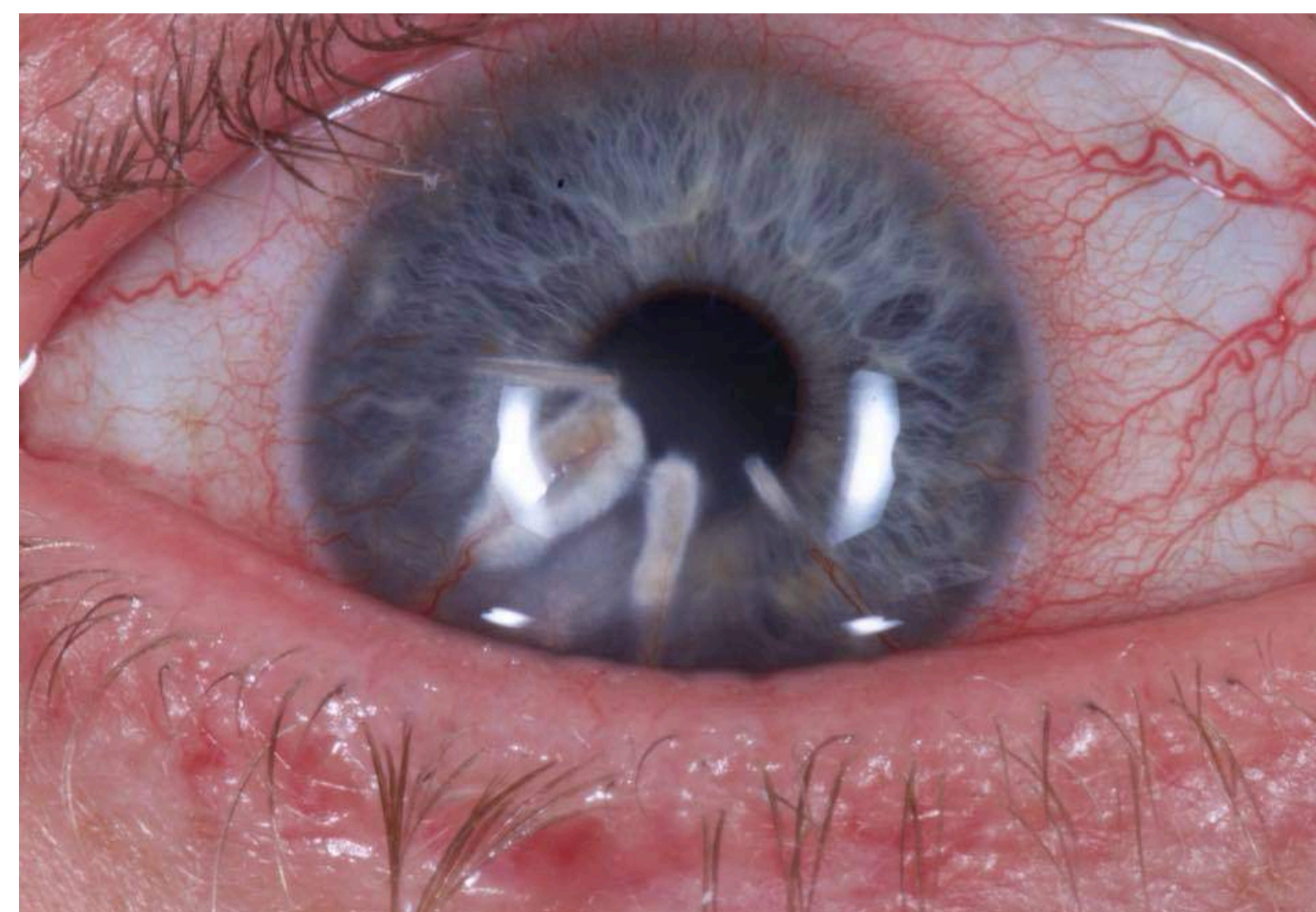
Over-Refraction

OD: Plano
OS: Plano

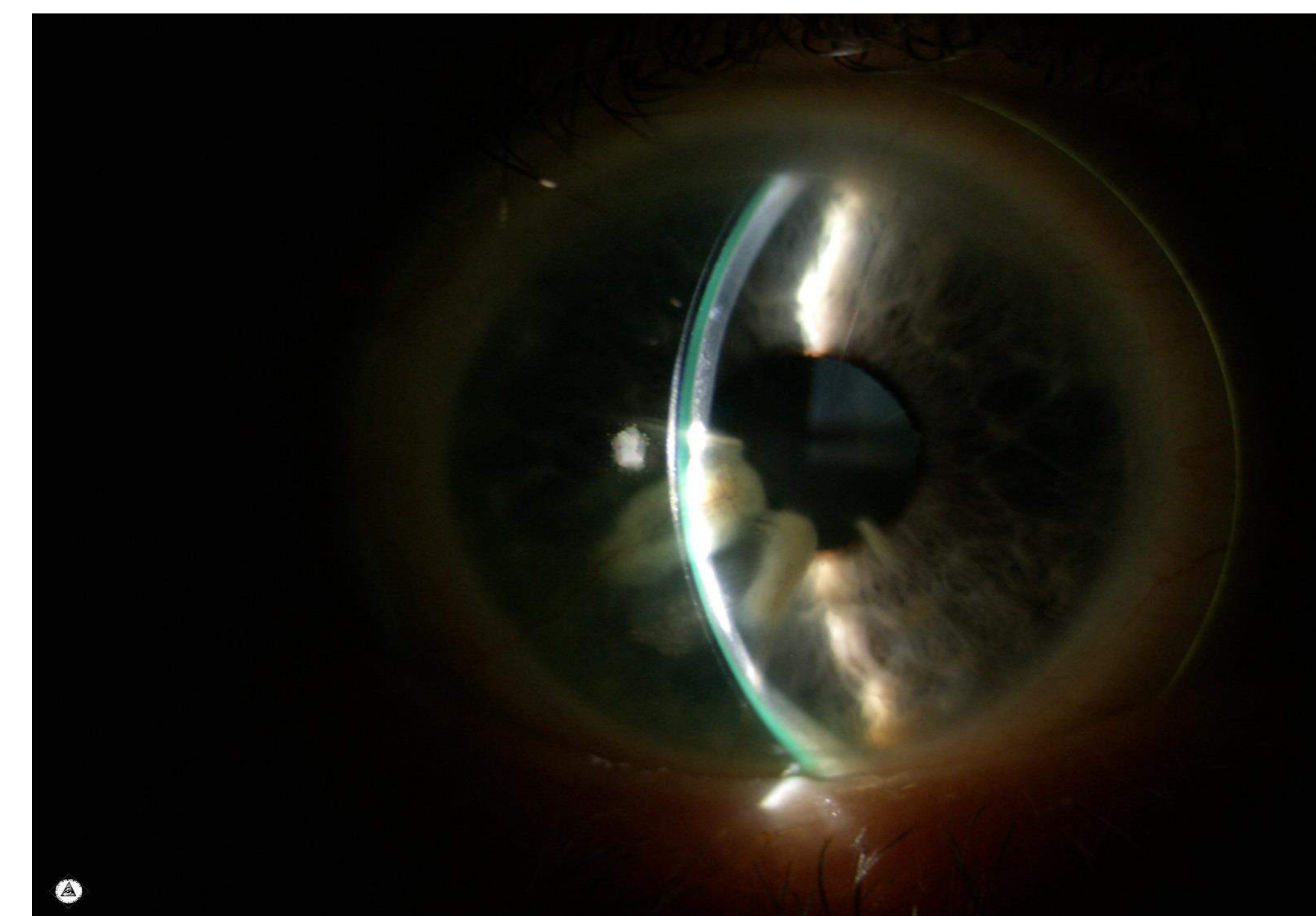
Cleaning Regimen

AM: LaciPure
PM: Optimum ESC and Unique pH

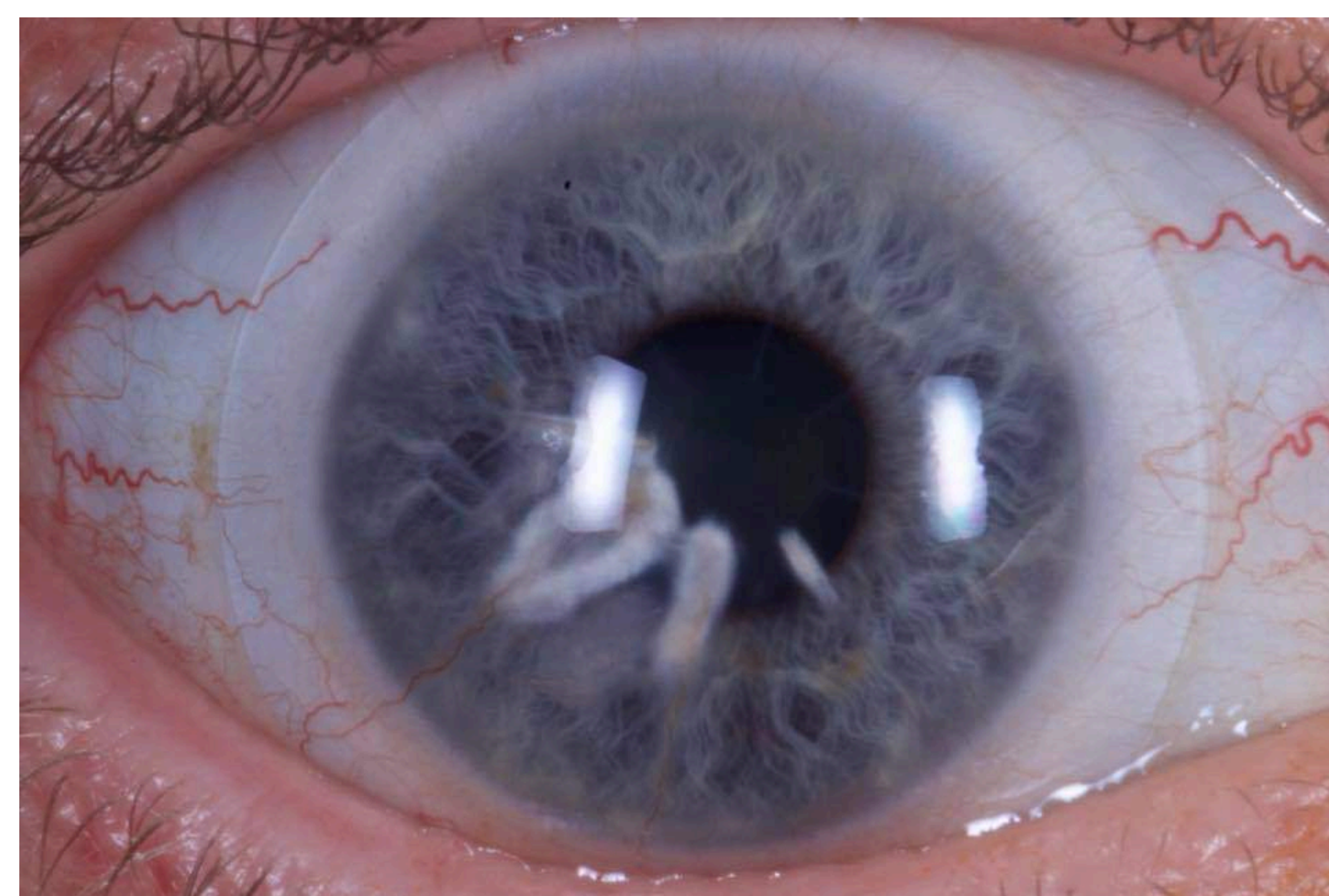
RESULTS



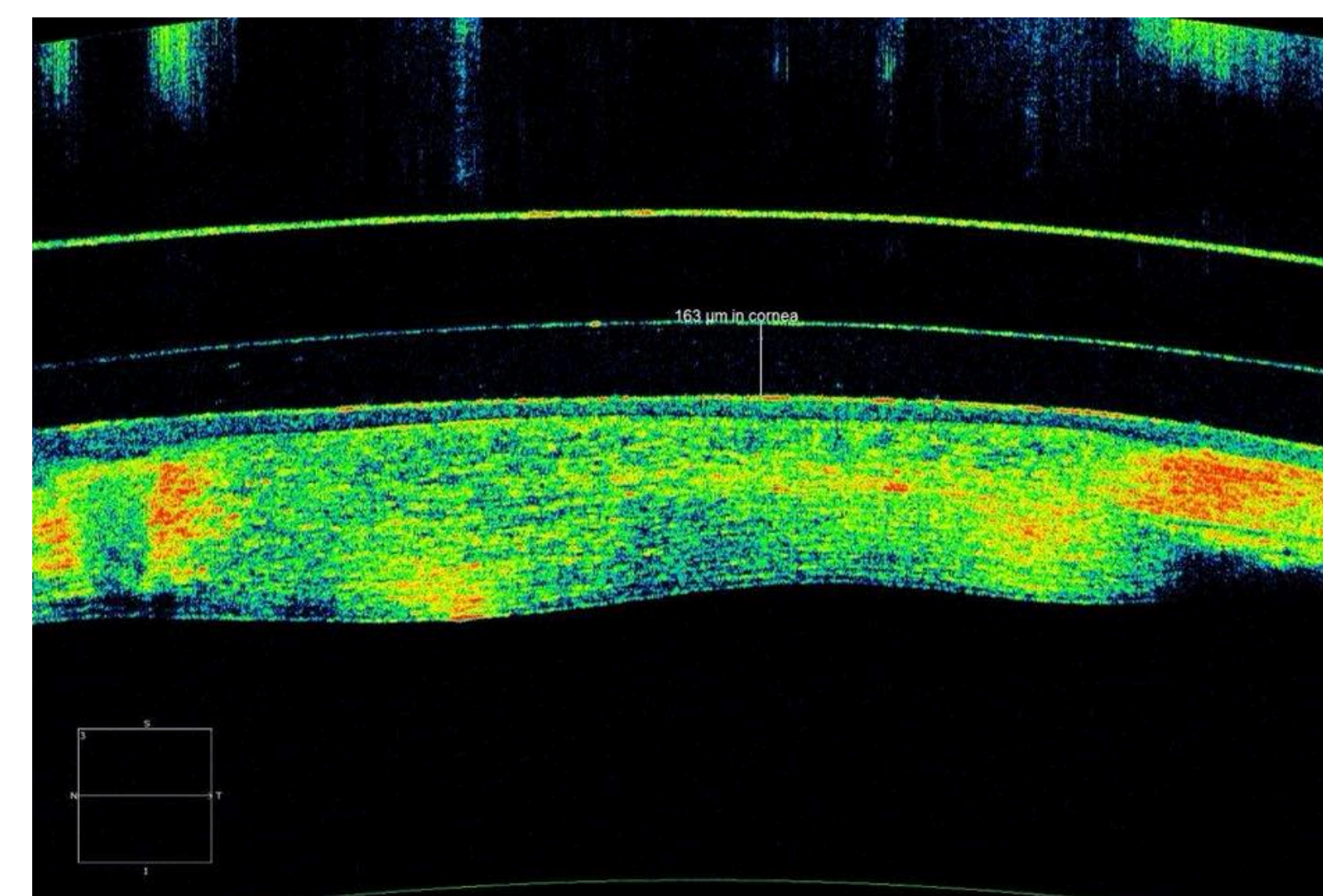
Right Eye At The Initial Visit



Optic Section View Of The Right Eye



Right Eye At 6 Week Progress Visit



OCT Of The Left Eye After 8 Hours of Wear Time
163 um Of Central Vault

DISCUSSION

At the 6-week follow up appointment, there was significant regression of neovascularization in both eyes. Conjunctival injection had also improved OU. The patient's vision improved to 20/20 OU at distance and near and he was able to comfortably wear his scleral lenses for 14-15 hours a day.

Oxygen transmission (Dk/t) is inversely correlated to lens thickness. As lens thickness increases, oxygen transmission decreases. Reduced oxygenation to the cornea can create countless issues: edema, neovascularization, increased risk of infection and inflammatory reactions, etc. In particular, oxygen to the limbal stem cells is vital for corneal repair and renewal.

The scleral lenses on both eyes had adequate central (269um OD, 163um OS) and limbal clearance. The tangential edge shows a smooth, even landing without conjunctival vessel impingement or edge lift.

In post-RK patients, SynergEyes VS is ideal due to its thin lens design, which allows for increased oxygen aiding in corneal healing.

The recommended follow up for scleral lenses is 10-14 days, 1 month, 3 months and every 6 months after that.

CONCLUSION

Sufficient corneal oxygenation is crucial for corneal rehabilitation from radial keratotomy complications and for maintaining corneal health.

REFERENCES

- Bennett, E.S., & Weissman, B.A. (2005). Clinical Contact Lens Practice. Philadelphia: Lippincott Williams & Wilkins
- Worp, E.V. (2015). A Guide to Scleral Lens Fitting. Forest Grove, OR: College of Optometry, Pacific University
- Reminton, L.A. (2012). Clinical Anatomy and Physiology of the Visual System (3rd ed.). St. Louis, MO: Elsevier Butterworth Heinemann.
- <https://synergeyes.com/professional/specialty-contact-lenses-scleral-vs/>
- <http://gpli.info/pdf/GPLISLSTSGuide11017.pdf>
- <http://www.meniconamerica.com/consumer/lens-care/gp/lacripure/>
- <http://www.meniconamerica.com/consumer/lens-care/gp/unique-ph/>
- http://www.loboblabs.com/store/product_info.php?products_id=42